

Isolated Giant Primary Splenic Hydatid Cyst: A Case Report

BELAGOUN.M.N*, HADJ SAID.M**, ZERKOUK.N***, C BOUKERT,
CHETOUANE.A*

* THENIA HOSPITAL – BOUMERDES, ** MEDEA HOSPITAL - MEDEA ***
BENISLIMANE HOSPITAL – MEDEA

ABSTRACT:

INTRODUCTION: Cystic lesions of the spleen are infrequent and usually diagnosed, incidentally. These lesions are rare and their differential diagnosis is very wide. Splenic hydatid cyst (HC) is uncommon and its isolated involvement is very rare ($<2\%$). In frequency order, it is the third affected organ after liver and lung, caused by infection with *Echinococcus granulosus* larvae leading to the development of cysts.

MATERIAL AND METHODS: We are presenting a case of isolated hydatid cyst of spleen in a thirty eight year old female patient with complaints of pain in the left hypochondrium, dyspepsia and features of gastritis for the last 1 year. The diagnosis was confirmed by Contrast enhanced CT scan (CECT) objectifying a giant cyst of spleen with wall thickening and hypo-dense content, the hydatid serology came back negative. The first diagnosis that was mentioned is isolated splenic hydatid cyst (endemic area).

RESULTS: Open splenectomy was performed; the operative consequences were simple. Macroscopic and microscopic appearance confirms the diagnosis of hydatid disease.

CONCLUSION The aim of this case report is to emphasize that the most important factor in diagnosing splenic hydatid cyst is the awareness of its possibility and the intraoperative precautions which will decrease morbidity and mortality in the postoperative period.

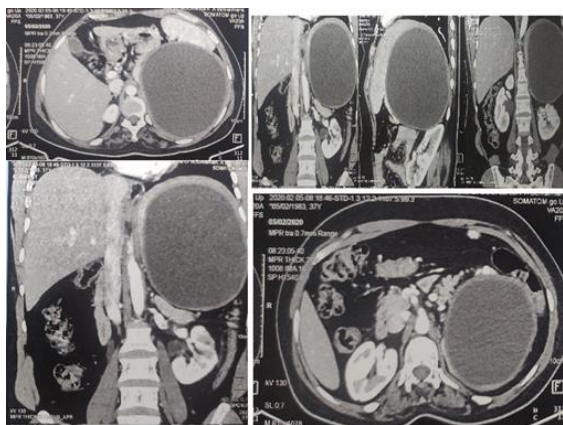
Key words: spleen, echinococcosis, Hydatid Disease

INTRODUCTION

Cystic lesions of the spleen are infrequent and usually diagnosed incidentally. These lesions are rare and their differential diagnosis is very wide. Splenic hydatid cyst (HC) is uncommon and its isolated involvement is very rare ($<2\%$) [1]. In frequency order, it is the third affected organ after liver and lung[3,4]. caused by infection with *Echinococcus granulosus* larvae leading to the development of cysts; It is prevalent in sheep grazing area. Humans are intermediate host. We are reporting a case of isolated hydatid cyst of spleen in a thirty eight year female patient who was treated by open splenectomy.

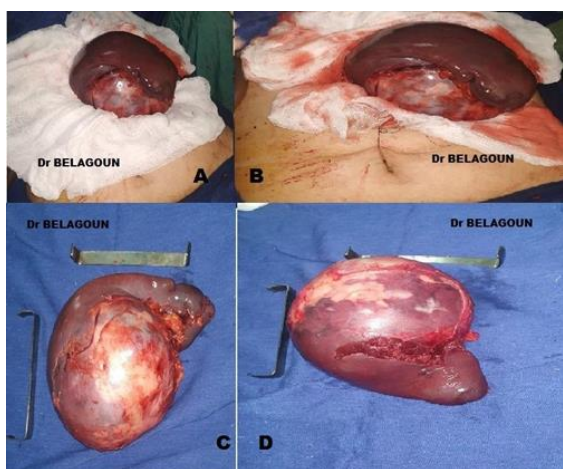
CASE REPORT:

thirty-eight-year-old female patient presented with complaints of pain in the left hypochondrium, dyspepsia and features of gastritis for the last 1 year; the patient live in rural house but there was no history of pet dogs or sheep at home. Abdominal examination showed no organomegaly. X-ray abdomen were unremarkable; An ultrasound abdomen showed a well-defined cystic lesion volume in the splenic parenchyma near the hilum showing thick internal membranes and echoes. The diagnosis was confirmed by Contrast enhanced CT scan (CECT) (Picture 01) objectifying a giant cyst of spleen (156X151X135 mm) with wall thickening and hypo-dense content. Routine laboratory tests, other than the indirect



Picture 01 : Contrast enhanced CT abdominal (CECT)

hemagglutination test for hydatid cysts were normal. X-ray chest was normal. The first diagnosis that was mentioned is isolated splenic hydatid cyst (endemic area). Splenectomy was proposed, and the vaccination schedule was produced (Pneumococcal and Influenzas vaccination)

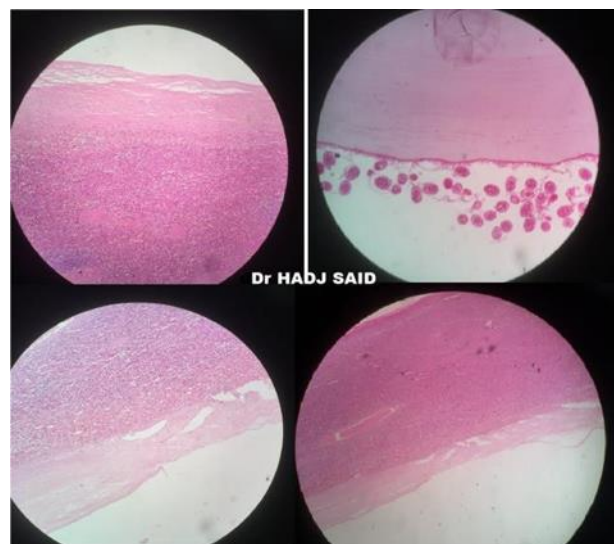


Picture 02: A/B Intraoperative view; C/D splenectomy and HC

In operating theater (Picture 02): via subcostal laparotomy; On exploration, we found a huge hydatid cyst in the spleen filling the entire left side of the abdomen and pushing the intestines.

Open splenectomy was performed after protecting the operating field with hydrogen peroxide, the operative consequences were simple. She left hospital on the fifth day.

Macroscopic and microscopic appearance confirms the diagnosis of hydatid disease. (Picture 03)



Picture 03: pathologic examination of surgical specimen

DISCUSSION:

Hydatid disease occurs mainly in sheep-grazing areas of the world. Man is an accidental host of *Echinococcus granulosus* after ingestion of eggs. Larva liberated from eggs penetrates the bowel mucosa to enter the portal system thereby spreading to various organs [2,11]. Although hydatid disease can affect any part of the body, cysts are found in the liver (55%–60%), lungs (30%), kidney (2.5%), heart (2.5%), bones (2%), muscles (1%), brain (0.5%) and spleen (1.5%) [1,11].

Splenic hydatid cysts are generally asymptomatic. Diagnosis is usually established incidentally during investigation of unrelated symptoms. When the cyst reaches an advanced size, the patient presents with a painful mass in the left hypochondrium [5,6,10]. Other initial presentations include renal arterial compression and systemic hypertension or

rupture of the splenic hydatid cyst to the other organs [5,10].

Diagnosis is confirmed by abdominal ultrasound and CT scan. On ultrasound of abdomen, splenic hydatid cyst may present as an anechoic spherical cystic lesion with hyperechoic marginal calcification. CT abdomen confirms the cystic lesion with or without daughter cysts within the spleen. Other tests are cassoni test and enzyme linked immunosorbent assay (ELISA)

The differential diagnosis for splenic hydatid cysts includes other splenic cystic lesions such as epidermoid cysts, pseudocysts, splenic abscesses, hematomas and cystic neoplasms of the spleen [7,8,10].

Owing to the risk of spontaneous or traumatic rupture, splenic hydatid cysts are usually treated surgically [5,8,10]. The standard treatment is total or partial splenectomy. Cyst fluid can be drained with puncture and aspiration to reduce the intracystic pressure, but splenectomy without puncturing the cyst is preferable [8,9,10].

CONCLUSION:

The aim of this case report is to emphasize that the most important factor in diagnosing splenic hydatid cyst is the awareness of its possibility and the intraoperative precautions which will decrease morbidity and mortality in the postoperative period.

References

[1] A. Gupta, A. Kakkar, M. Chadda, et al., A Primary intrapelvic Hydatid cyst presenting with foot drop and a gluteal swelling, *Br. J. Bone Joint Surg.* 808 (1998) 1037–1038.

[2] N. Sekar, K.K. Madhavan, R.V. Yadav, R.N. Katara, Primary retroperitoneal hydatid cyst: a case report and review of literature,

J. PostGraduate Med. 28 (1982) 112–148.

[3] C. Dziri, Hydatid disease: continuing serious public health problem: introduction, *World J. Surg.* 25 (2001) 1–3.

[4] D.P. McManus, W. Zhang, J. Li, et al., Echinococcosis, *Lancet* 362 (2003) 1295–1304.

[5] Celebi S, Basaranoglu M, Karaaslan H, et al. A splenic hydatid cyst case presented with lumbar pain. *Intern Med* 2006;45:1023-4.

[6] Kiresi DA, Karabacakoglu A, Odev K, et al. Uncommon locations of hydatid cysts. *Acta Radiol* 2003;44:622-36

[7] Pedrosa I, Saíz A, Arrazola J, et al. Hydatid disease: radiologic and pathologic features and complications. *Radiographics* 2000;20: 795-817.

[8] Durgun V, Kapan S, Kapan M, et al. Primary splenic hydatidosis. *Dig Surg* 2003;20:38-41.